

LETTER TO EDITOR

Post-syncope trauma should be considered in COVID-19 patients

Fatemeh Ghanbarpour¹, Seyed Mohammad Ghahestani², Rayka Sharifian^{3*}

1. 17- Shahrivar Hospital; Mazandaran University of Medical Sciences, Amol, Iran.

2. Children Medical Center, Tehran University of Medical Sciences, Tehran, Iran.

3. Men's Health and Reproductive Health Research Center, Shahid Beheshti University of Medical Sciences, Tehran, Iran.

Received: June 2020; Accepted: June 2020; Published online: July 2020

Cite this article as: Ghanbarpour F, Ghahestani Seyed M, Sharifian R. Post-syncope trauma should be considered in COVID-19 patients. Mens Health J. 2020; 4(1): e11.

Dear Editor,

In December 2019, a new form of respiratory infection associated with coronavirus appeared in Wuhan, China. As of today, COVID-19 has spread all around the world. There have been 9.24 million confirmed cases and 477,000 deaths globally. Fever, cough, and coexistence chest or back pain are some of the most reported symptoms of COVID-19. Although syncope is not a primary symptoms, we see patients passing out in the street after coronavirus pandemic. Up to now, syncope due to COVID-19 has only been reported by CHANTAL and coauthor in a 79 year-old patient. (1) There is no available data on syncope in COVID-19 patients. This is while some patients have been referred to us purely for their symptoms of fainting. Etiology of fainting in COVID-19 may be the product of orthostatic hypotension and vasovagal syncope due to dehydration. Increasing pressure in thoracic cavity during sequential cough may induce "cough syncope". (2) On the other hand, coughing can cause situational syncope. SARS-Coronavirus-2 is a predisposing factor of damage myocardium in patients with underlying cardiovascular disease, despite the fact that the exact mechanism is unknown.

Bonow and colleague hypothesize that severe systemic inflammatory stress induced by cytokines can de-stabilize atherosclerotic plaques. Myocardial injury is a consequence of acute coronary event due to plaque rupture.(3) Arrhythmia secondary to myocardial damage may cause syncope. Treatment of COVID-19 patients with oral agents like chloroquine is another etiology of syncope. Chloroquine causes venodilation and reduces preload and afterload, then may induce

vasovagal syncope. QT prolongation and cardiotoxicity were observed after chloroquine administration too. COVID-19 manifestations in severe forms consist of hypoxia and respiratory distress and acute severe hypoxia. Then, hypoxia in this patients may induce "Hypoxic or reflex anoxic Syncope".(4)

One of the increasing concerns during the Coronavirus pandemic is trauma as a result of passing out. Pezeshkan Sepid Iran, a social network of medical workers, reported a 65 years old female with right intertrochanteric fracture due to falling down. She was confirmed to host COVID-19 virus by lung high-resolution computed tomography (figure 1). (5) Syncope may be the main etiology of accident and trauma as a result of COVID-19. Therefore, we should consider a preventive strategy to reduce its chances. We recommend that trauma patients referred to emergency department due to unexplained fall with or without dry cough or other redflags of COVID-19 infection be screened by chest low dose CT scan.

References

1. Tape C, Byrd KM, Aung S, Lonks JR, Flanigan TP, Rybak NR. COVID-19 in a patient presenting with syncope and a normal chest X-ray. Rhode Island medical journal (2013). 2020;103(3):50.
2. Dicipinigaitis PV, Lim L, Farmakidis C. Cough syncope. Respiratory Medicine. 2014;108(2):244-51.
3. Bonow RO, Fonarow GC, O'Gara PT, Yancy CW. Association of coronavirus disease 2019 (COVID-19) with myocardial injury and mortality. JAMA cardiology. 2020.
4. Westendorp R, Blauw GJ, Fr  lich M, Simons R. Hypoxic syncope. Aviation, space, and environmental medicine. 1997;68(5):410-4.
5. <https://www.instagram.com/s/aGlnaGxpZ2h0OjE3OTE5>

*Corresponding Author: Rayka Sharifian; Address: Men's Health and Reproductive Health Research Center, Shahid Beheshti University of Medical Sciences, Tehran, Iran. Email: Sharifian.rayka@sbmu.ac.ir, Phone: +989358552104



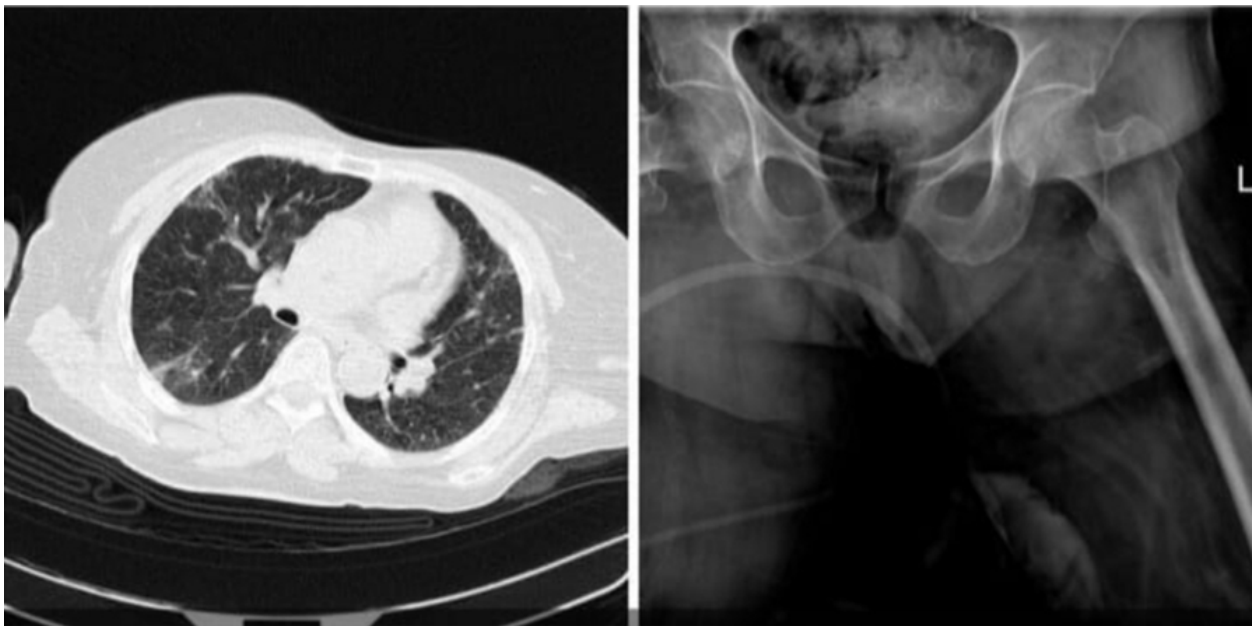


Figure 1: a 65 year-old COVID-19 patient with intertrochanteric fracture due to falling.

MTYyNzY5MzgwODk3?igshid=hx4h24ydiqp3&story_
media_id=2280664721889849732_9019447785